




Tissue Regeneration Concept – In a One-Step Procedure.

# Secures the Quality of Your Work.



# Secures the Quality of Your Work.

## The Nature.

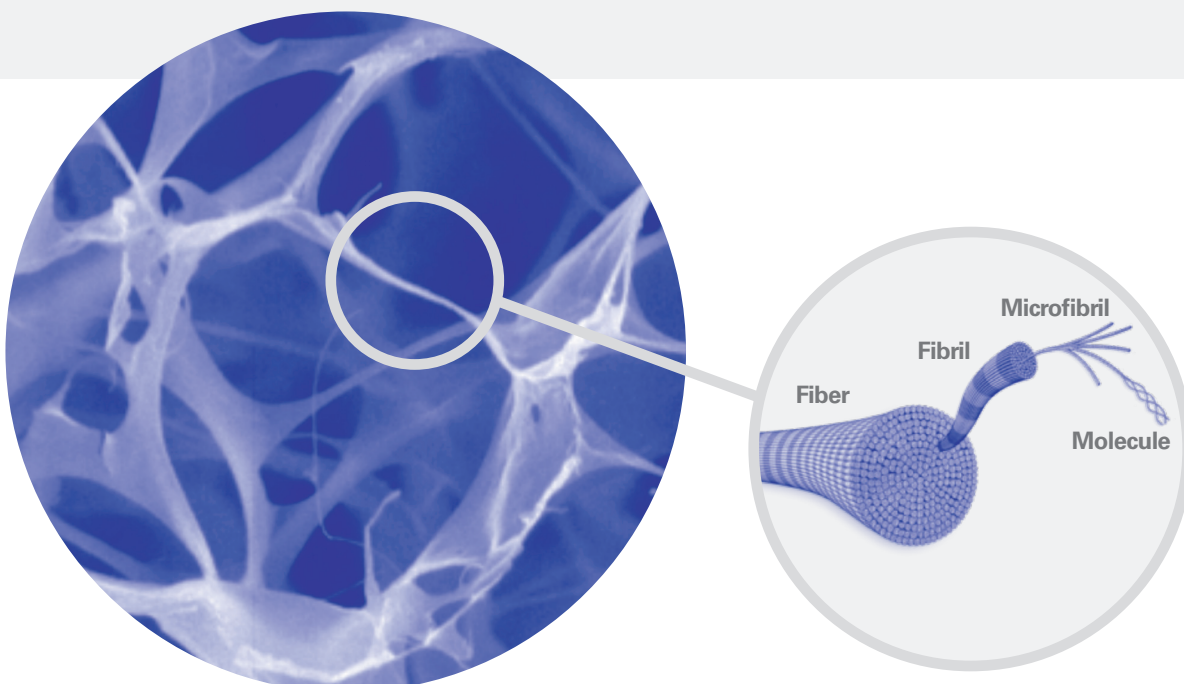
The extracellular matrix (ECM) is responsible for the structure and mechanics of the human body. It consists of a three dimensional network of different proteins and proteoglycans connecting all cell types in body tissue.

Connective tissue like skin, bone, tendon and cartilage consist mainly of ECM Collagens are key proteins of the ECM and play an essential role for its biomechanical characteristics. Each kind of tissue comprises a characteristic set of specific types of collagen to ensure tissue coherence and function.<sup>1</sup>

The main types of collagen in skin are I, III, and V.<sup>2</sup> In the deeper layer of the skin, called the dermis, the collagen forms an interwoven alloy-like fiber network stabilized by intermolecular crosslinking. Fibroblasts are located in this fiber network and produce new collagen to maintain the tissue quality.

The collagen fiber network initially starts with soluble collagen produced as single molecules comprising the native collagenous triple-helical structure. These thread-like molecules self-assemble to form bundles and subsequently fibrils which then merge to form large fibers and finally build a the three dimensional fiber network, the collagen matrix (Fig. 1).

**Fig. 1: Collagen Network**



The connection and interaction between fibroblasts and collagen fibers in the network is mediated by specific cell-surface receptors such as integrins.<sup>3</sup> These specific receptors are capable of distinguishing between native, triple-helical collagen structures and denatured collagen sequences which lack the triplehelical arrangement. Therefore, only native structures presenting the triplehelix can serve as attachment sites for cells and interact with the living cells.

Another key protein of the ECM is elastin. The elastic properties of connective tissue depend largely on the presence of elastic fibers in the ECM.<sup>4</sup> The highest concentration is found in those tissues that are subject to continuous physical deformation during body movement, i.e. the flexible skin.

Both collagen and elastin play an active role in skin quality. The flexible properties of the skin can be attributed to elastic fibers, whereas the resistance to tensile forces is mediated by the collagen fiber network. In a synergistic manner, both are responsible for the pliability, elasticity, and integrity of human skin.<sup>1</sup>

1 Connective Tissue and Its Heritable Disorders. Molecular, Genetic, and Medical Aspects, Editors: P. Royce, B. Steinmann, Wiley & Sons, 2nd edition 2002.  
2 Leitinger B, Hohenester E. Mammalian Collagen receptors Matrix Biol. 2007 Apr;26(3):146-55. Epub 2006 Nov 10. Review.  
3 Zhang et al. Interaction of primary fibroblasts and keratinocytes with extracellular matrix proteins: contribution of  $\alpha 2\beta 1$ -integrin. J Cell Sci 2006; 119:1886-1895.  
4 Kielty CM, Sherratt MJ, Shuttleworth CA. Elastic fibres, J Cell Sci 2002;115, 2817-2828.

# Secures the Quality of Your Work.

# The MatriDerm<sup>®</sup> Matrix.

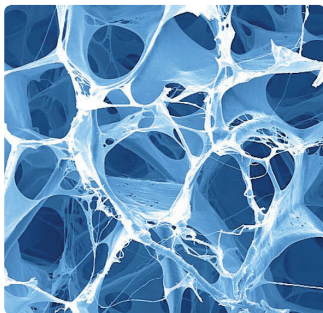
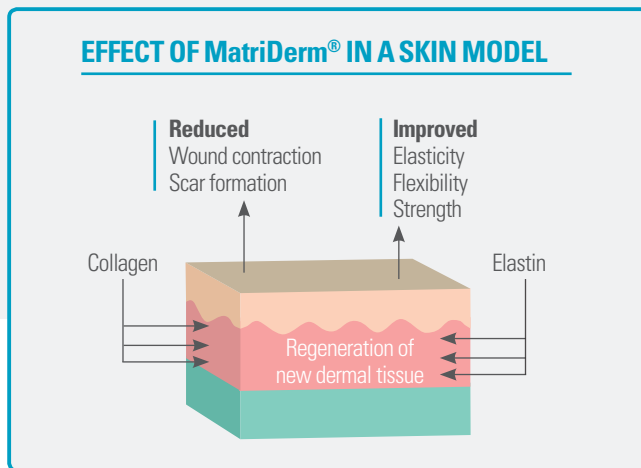
**MatriDerm<sup>®</sup>** was developed to improve the healing of full-thickness wounds compared to the gold standard, which is the sole application of split-thickness skin graft.

**The goal was to create a matrix that provides a natural structure that fosters**

- Immediate ingrowth of cells
- Fast re-vascularization
- Structured tissue regeneration

**Overcome the drawbacks of wound healing**

- Contracture
- Scar formation
- Insufficient tissue elasticity

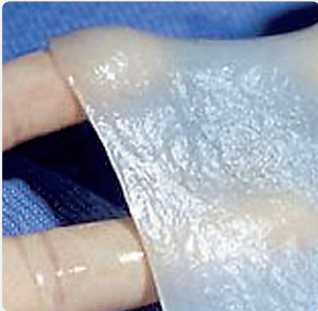

Three-dimensional open pore structure of the collagen-elastin matrix MatriDerm<sup>®</sup>

The core composition of **MatriDerm<sup>®</sup>** is skin collagen type I, III and V and solubilized elastin is supplemented.

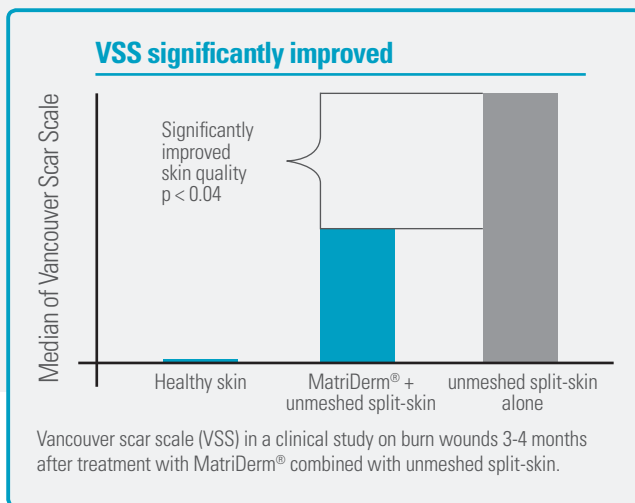
The matrix is processed with our proprietary **Advanced CryoSafe<sup>™</sup> Technology** that allows

- Maintenance of the bioactive properties of native collagen
- Creation of a highly porous matrix by physical cross-linking without any chemical agents
- Provision of a flexible and stable device in dry and wet states



**MatriDerm®** is a collagen-elastin scaffold which supplies the missing dermal component in a split-thickness skin graft enabling it to function as a full-thickness skin graft.<sup>1</sup>

Rehydrated MatriDerm® adapts smoothly to any surfaces



Modified Ryssel, Burns 2008.

### Clinical Advantages

- Cost effective one-step procedure
- Reliable dermal regeneration
- Excellent scar quality
- Faster patient rehabilitation
- Shortened hospital stay

### Clinical Safety

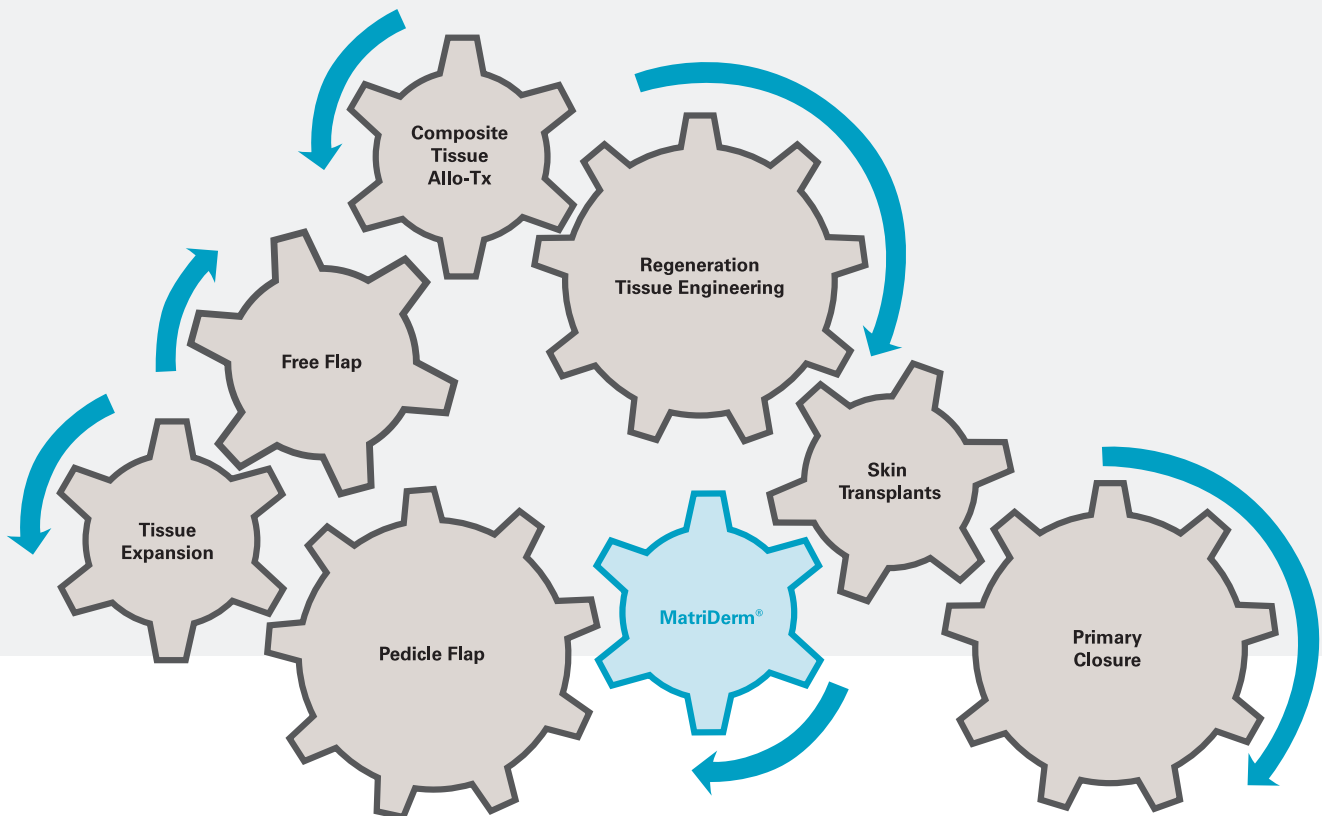
- Over 5.000 patients
- No side effects reported

<sup>1</sup> Haslik W, Kamolz LP, Manna F, Hladik M, Rath T, Frey M. Management of full thickness skin defects in the hand and wrist region: first long-term experiences with the dermal matrix MatriDerm®. J Plast Reconstr Aesthet Surg 2010;63(2): 360-4.

# Secures the Quality of Your Work. The Practice.

## MatriDerm®: Complementing Therapeutic Options

MatriDerm® offers additional options in the surgical tool box of wound healing. It completes your established range of tools and supports your work.



Modified Knobloch, Chirurg 2010; 81: 441-446.

The overall goal of surgical treatment of full-thickness defects is the restoration of normal function and aesthetic appearance. The repertoire of reconstructive surgery techniques is constantly progressing and offers a broad variety of options. Recently the overview on reconstructive procedures has been described as clockwork.<sup>1</sup> This illustration reflects the freedom to choose the appropriate surgical procedure as well as the possibility to combine different methods to achieve the best outcome for the patient.

**MatriDerm**<sup>®</sup> enhances your treatment portfolio of full-thickness wounds and deep partial defects.

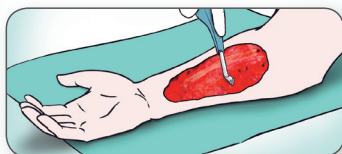
- **MatriDerm**<sup>®</sup> gives a split-thickness skin graft the quality of a full-thickness graft without donor site morbidity
- In selected cases, **MatriDerm**<sup>®</sup> plus split-thickness skin graft may be a cost-effective flap alternative
- **MatriDerm**<sup>®</sup> plus split-thickness skin graft can be an alternative to avoid additional surgeries to thin out bulky flaps

# Secures the Quality of Your Work.

# The Cost Effective One-Step Procedure.

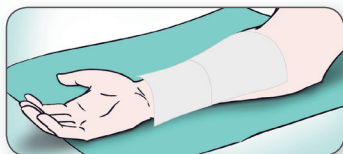## 1 Wound Bed Preparation

MatriDerm® is for use in full- and deep partial-thickness wounds

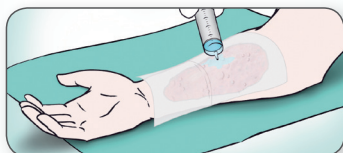

- Wound bed preparation to a clean and well vascularized wound
- Make sure the wound bed is free of iodine containing antiseptic agents and enzymatic debridement agents

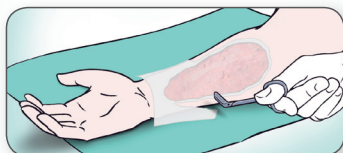
## 2 Application of MatriDerm®



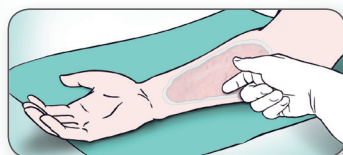
- Dry application of MatriDerm® is recommended
- If more than one MatriDerm® sheet is used, the sheets should overlap by approximately 2-3 mm



- Rehydration in the wound can be achieved with sterile saline. Do not use saline solution over room temperature



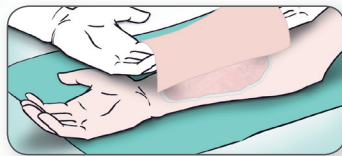
- Cut the matrix to overlap the wound edges by 2 mm



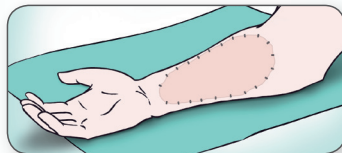
- MatriDerm® must be in direct contact with the wound bed
- If necessary: Carefully remove air bubbles



### 3 Application of the skin graft



- MatriDerm® 1 mm should be immediately covered with a STSG\*
- Unmeshed graft is preferred. If necessary meshed graft can be used. Mesh 1:1.5 has shown good results
- Direct contact between the matrix and the skin graft is essential

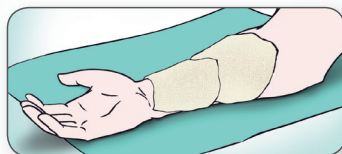


- If more than one piece of MatriDerm® is required, it is advisable to have the seams of the STSG\* at right angles to the MatriDerm® seams
- MatriDerm® and STSG\* should be attached with sutures, staples or fibrin glue

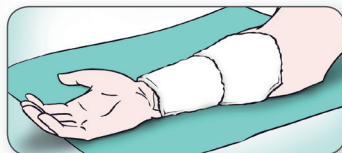### 4 Dressing

Because of the fragile nature of the graft, dressing change before day 5 is not recommended.

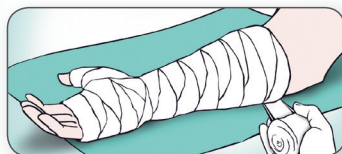
At the first dressing change the normal pink color of the graft may be diminished due to the presence of the matrix.



- Recommended dressing is
- 5-6 layers of fatty gauze, e.g. Jelonet®



- 3-4 layers of bulky dressing



- Tight bandaging. Negative pressure wound therapy may be used. Immobilisation whenever possible

# Secures the Quality of Your Work. The Mode of Action.

A full-thickness wound is a combined loss of epidermal and dermal layers and may occur under various circumstances, i.e. trauma, third degree burns and reconstructive surgery. Despite successful defect coverage, unfavorable and unstructured scar formation is the major concern associated with the outcome. Therefore, successful regeneration of dermal tissue is important in both functional and aesthetic outcome.

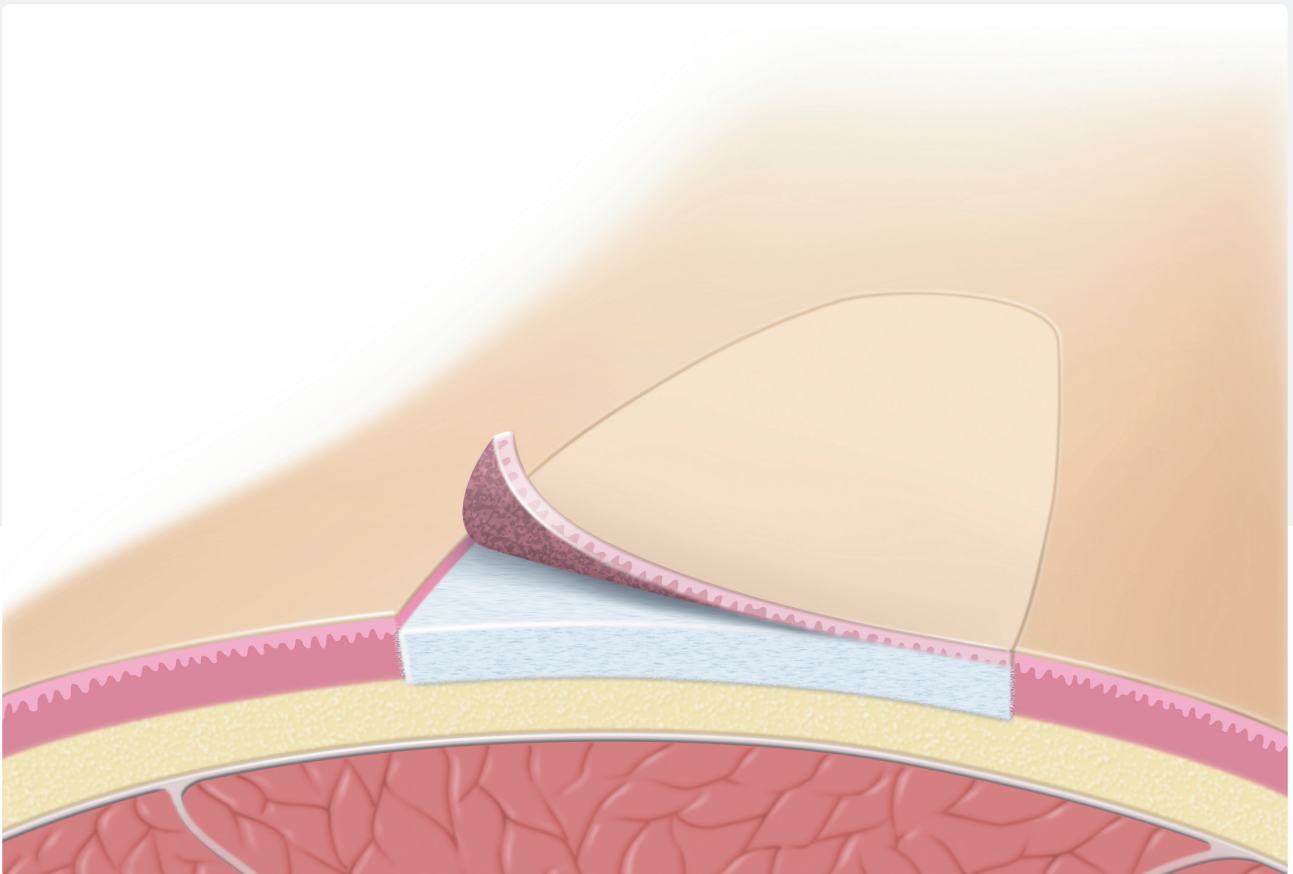


Fig. 1: Full-thickness wound covered with MatriDerm® and split-thickness skin graft

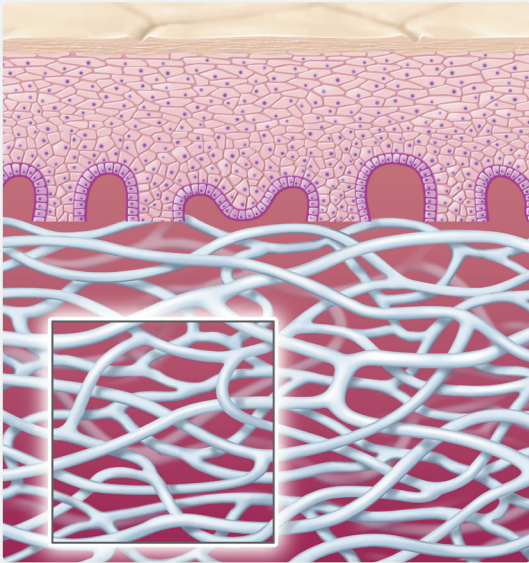


Fig. 2: MatriDerm® covered with split-thickness skin graft




Fig. 3: Invading platelets activated by binding to collagen

The key factor of the success **MatriDerm**® is the preservation of the native biological properties of the collagen-elastin-matrix due to our **Advanced CryoSafe™ Technology**. **MatriDerm**® is a unique collagen elastin-matrix which serves as a dermis replacement scaffold (Fig. 1).

In a cost effective one-step procedure. **MatriDerm**® is placed on the wound bed and covered with a split-thickness skin graft (Fig. 2).

Subsequently, **MatriDerm**® supports all crucial steps of skin regeneration to secure an optimal result for both – patient and physician.

### **Support Cell Invasion**

The process of wound healing starts with hemostasis. Blood platelets enter the collagen-elastin matrix and are activated by the native collagen structure. Activation leads to clotting which starts the release of growth factors (Fig. 3). This initiates cell migration and supports proliferation. In a wound-healing situation, regeneration of tissue requires migration and proliferation of tissue-forming cells e.g. fibroblasts and endothelial cells. Originating from the non-injured periphery they invade the wounded area from the wound margins. **MatriDerm**® provides a three-dimensional native collagen matrix to facilitate this important cell migration.

**MatriDerm**® provides a native three dimensional collagen matrix to facilitate cell migration.

## Matrix Structure Supports Cellular Activation

Invading cells, such as fibroblasts and endothelial cells actively use the collagen fibers of the collagen-elastin matrix as guiding ridges<sup>1</sup> for migration (Fig. 4). Specific binding sites present on the native collagen fibers of **MatriDerm**<sup>®</sup> play a vital role in this mechanism: Collagen receptors on the cell surface of the migrating cells, especially integrins, exclusively recognize native triple-helical collagen structures (Fig. 5) and do not bind to denatured collagen sequences.<sup>2</sup> Therefore, only the native collagen of **MatriDerm**<sup>®</sup> is able to provide sites for cell attachment and mobility.

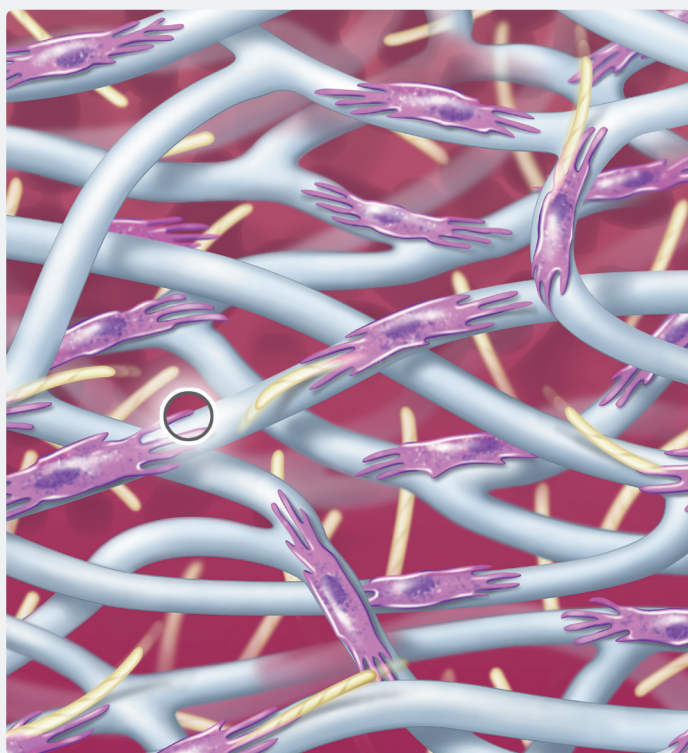


Fig. 4: Fibroblasts are guided and activated by native collagen to produce body-own collagen

Besides simple attachment, integrins are also responsible for the outside-in-signaling from the surrounding matrix towards the cell's interior. Cell binding to the native collagen initiates cell-specific response, starts signaling cascades and pathways which influence proliferation and protein expression.

The native collagen of **MatriDerm**<sup>®</sup> is capable of activating cells via collagen-specific cell surface receptors by providing suitable binding sites.

## Elastin and Collagen: Accelerated Neoangiogenesis

After invasion of **MatriDerm**<sup>®</sup>, cells grow in number and synthesize the different components of the extracellular matrix in order to rebuild tissue structure and function (Fig. 4).

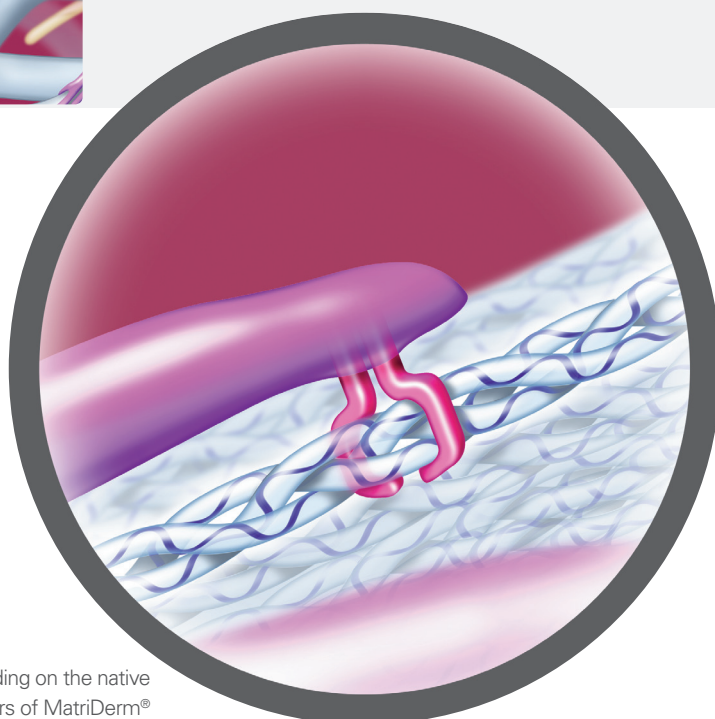


Fig. 5: Integrin binding on the native collagen fibers of **MatriDerm**<sup>®</sup>

1 Zhang et al. Interaction of primary fibroblasts and keratinocytes with extracellular matrix proteins: contribution of  $\alpha 2\beta 1$ -integrin. *J Cell Sci* 2006; 119:1886-1895.  
2 Leitinger B, Hohenester E. Mammalian Collagen receptors *Matrix Biol.* 2007 Apr;26(3):146-55. Epub 2006 Nov 10. Review.

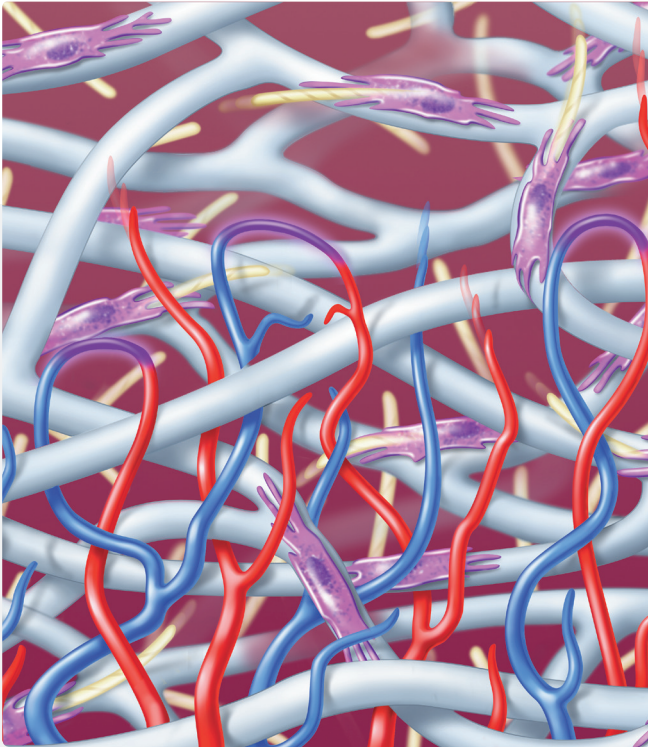


Fig. 6: Formation of micro-vessels

To supply nourishment to actively-producing fibroblasts, endothelial cells start forming micro-tubes in order to connect the newly-formed tissue with the blood circulation in the uninjured periphery of the wound (Fig. 6). In tissue regeneration, this neo-angiogenesis is an important process, during which the extracellular matrix plays a key role.<sup>3</sup>

**MatriDerm®** enhances neo-angiogenesis in 2 ways:

The native collagen fiber matrix guides and protects the newly-formed micro-vessels.

Additionally, solubilized elastin exhibits multiple biological effects important for angiogenesis. Acting as a matrix derived cytokine (matrikine)<sup>4</sup>, elastin positively influences the proliferation of vessel forming cell types.<sup>5</sup>

## Reduced Scar Contraction and Enhanced Tissue Elasticity

**MatriDerm®** has been designed to support cell attachment, cell invasion and provide a guiding structure. Moreover, it provides the proper rigidity in cell-matrix interaction. Research shows that matrix mechanics influence fibroblasts in their biomechanical activity during the wound-healing process.<sup>6,7</sup> The specific rigidity of **MatriDerm®** modulates cell derived contractile forces resulting in a reduced contraction of the newly-formed dermal layers.

Secondly, solubilized elastin, the other component of **MatriDerm®** is known to influence the formation of elastic fibers by early induction of elastin synthesis as normally seen in the chain of wound-healing events.<sup>5</sup>

The synergy of matrix nativity, rigidity and the effects of solubilized elastin ensures a superior outcome of the newly formed dermal layer in comparison to application of split skin alone.

**MatriDerm®** secures the Quality of Your Work.

3 Eble JA, Niland S. The extracellular matrix of blood vessels. *Curr Pharm Des* 2009;15(12):1385-400. Review.

4 Duca et al. Elastin as a matrikine. *Crit Rev Oncol Hematol.* 2004; Mar;49(3):235-44.

5 Daamen et al. A biomaterial composed of collagen and solubilized elastin enhances angiogenesis and elastic fiber formation without calcification. *Tissue Eng Part A.* 2008; Mar;14(3):349-60.

6 Rhee S; Grinnel F. Fibroblast mechanics in 3D collagen matrices. *Adv Drug Deliv Rev* 2007;Nov 10;59(13):1299-305. Epub 2007 Aug 14. Review.

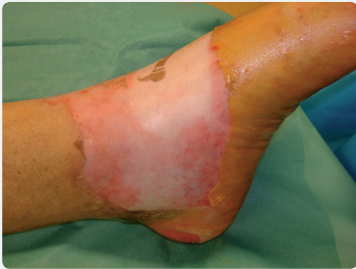7 Chiquet M. et al.; From mechanotransduction to extracellular matrix gene expression in fibroblasts. *Biochim Biophys Acta* 2009 May;1793(5):911-20. Epub 2009 Jan 31. Review.

8 Rysseel H. et al. The use of MatriDerm® in early excision and simultaneous autologous skin grafting in burns – A pilot study. *BURNS* 2008;93-97.

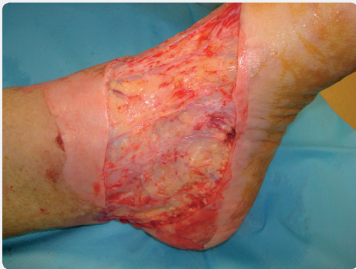Secures the Quality of Your Work.

# MatriDerm<sup>®</sup> in Burn Surgery.

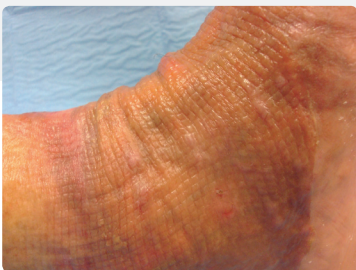## Foot Burn\*



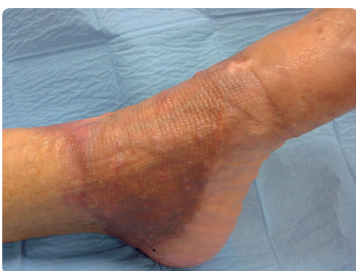Acute III° Burn  
of the instep of  
the foot



**Day 0**  
Wound excision



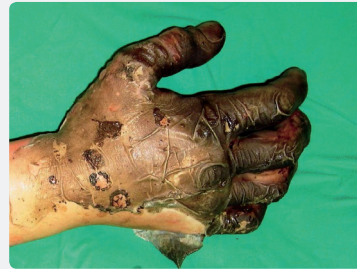**Day 39 p.o.**  
Early extension and  
flexation possible



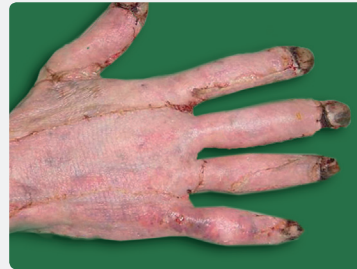Full range of motion

\* Courtesy of E. Dantzer, Toulon, France

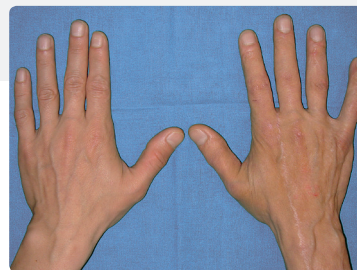
## Hand Burn\*\*



**Day 0**  
Acute III° Burn



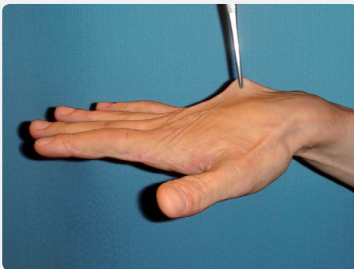
**Day 11 p.o.**  
Good take



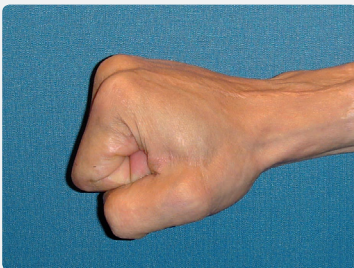**1 year follow-up**

\*\* Haslik W. et al., 2007, Burns

## Hand Burn

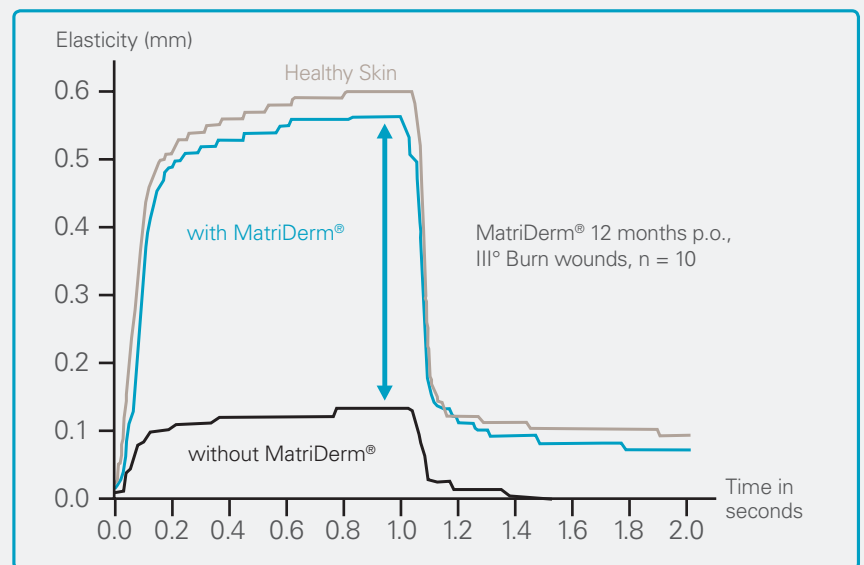


Excellent elasticity and pliability



Full range of motion

## Determination of Skin Elasticity via Cutometer-Measurement



L.P. Kamolz presented at the ISBI meeting in Montreal 2008.

## Surgical Challenges:

- Earliest possible permanent closure
- Efficient and safe procedure
- Both functional and aesthetic outcome

## MatriDerm® Tissue Regeneration Concept

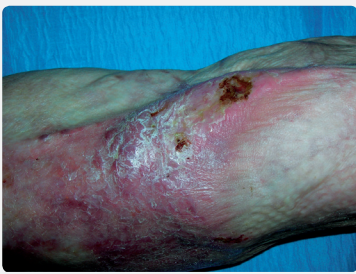- Quality in Efficacy: Cost effective one-step procedure
- Quality in Structure: Turns a split-thickness skin graft into full skin quality
- Quality of Life: Superior functional and aesthetic outcome

Secures the Quality of Your Work.

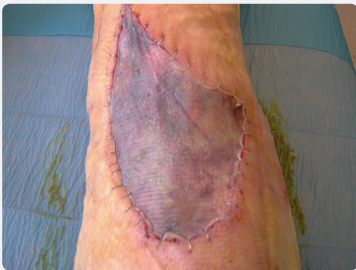# MatriDerm<sup>®</sup> in Reconstructive Surgery.

## Scar Reconstruction

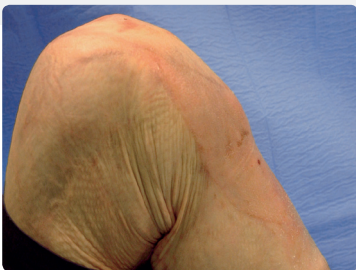34 year old patient with chronic wound on the left knee\*



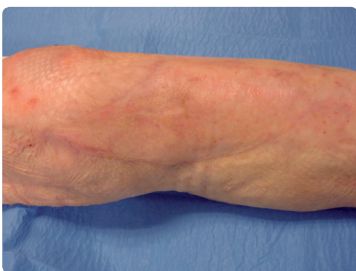**Day 0**  
Painful,  
unstable scar



**Day 4 p.o.**  
First dressing  
change



**8 months p.o.**  
Stable wound  
closure, full range of  
motion, superior skin  
elasticity

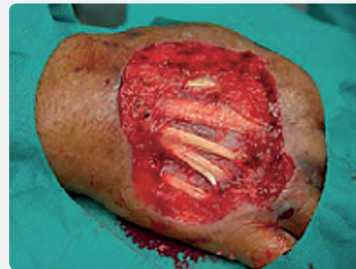

**15 months p.o.**

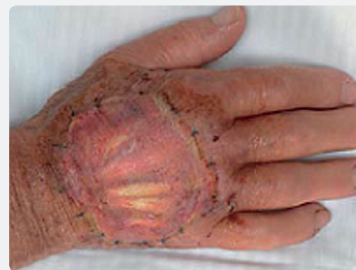\* Courtesy of E. Dantzer, Toulon, France

## Exposed Tendons

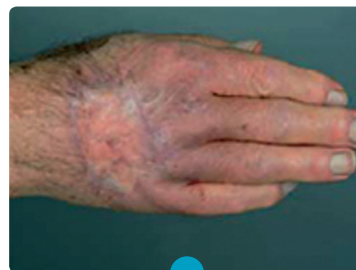80 year old patient with skin tumor on the dorsum of the hand. Co-morbidities: Chronic heart failure NYHA III, diabetes, absolute arrhythmia



**Day 0**  
Deep wound  
with exposed  
tendons



**Day 7 p.o.**  
Good take rate  
of the STSG



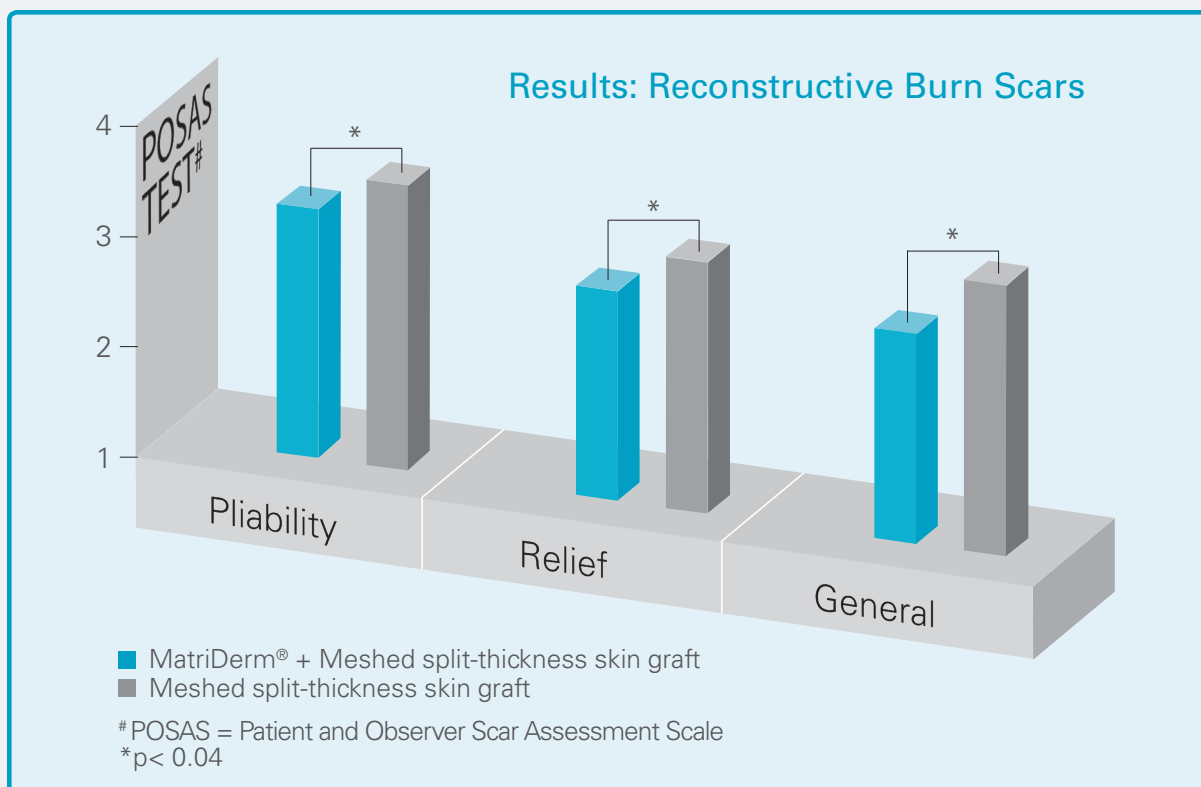
**6 months p.o.**  
Excellent functional  
and aesthetical  
outcome

*"The aesthetic outcome was good, especially considering the excellent risk-benefit-ratio. The functional outcome was satisfactory for the patient."<sup>1</sup>*

T. Wetzig et al.



## The Only Dermal Substitute With Proven 12 Year Benefit<sup>2</sup>



### Surgical Challenges:

- Reduction of scar formation
- Full joint functionality
- Restoration of patient's quality of life

### MatriDerm® Tissue Regeneration Concept

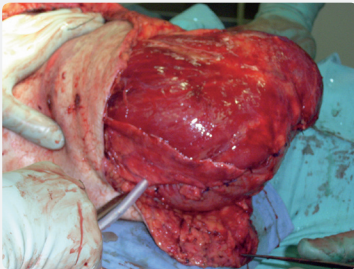
- Quality in Efficacy: Cost effective one-step procedure
- Quality in Structure: Turns a split-thickness skin graft into full skin quality
- Quality of Life: Superior functional and aesthetic outcome

Secures the Quality of Your Work.

# MatriDerm<sup>®</sup> in Trauma Surgery.

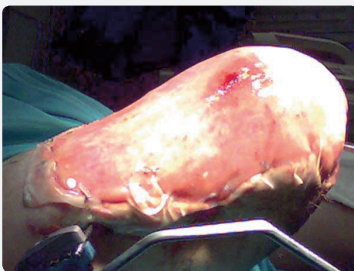## Amputation

Crush trauma with severe soft tissue defects and deglovement\*

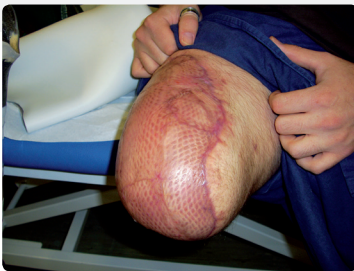

### Day 0

Operation site after above knee amputation



**Day 16 p.o.**  
MatriDerm<sup>®</sup> and STSG in one step



**12 weeks p.o.**  
Good functional and aesthetic outcome

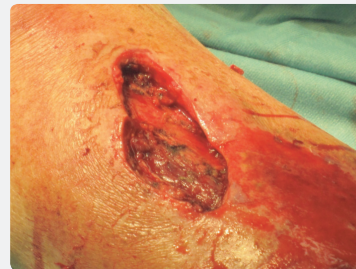\* Courtesy of Dr. Laun, Berlin, Germany

## Open Fracture of The Tibia

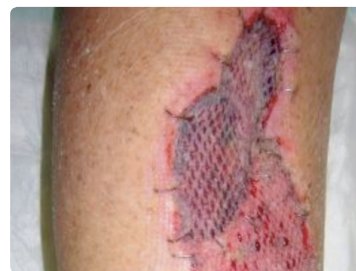In combination with a full-thickness defect and distal deglovement. Remaining dermis and sub-dermis additionally detached from fascia.\*\*

### Treatment:

- Medullary nail
- Debridement of wound and coverage of the full-thickness defect with MatriDerm<sup>®</sup> and STSG in one step; Relining of the detached skin area with MatriDerm<sup>®</sup> in the distal region
- VAC-therapy for 5 days

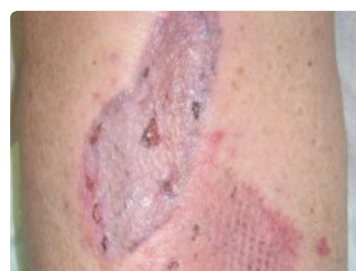

**Day 0**



**Day 5 p.o.**

After removal of VAC; good take rate of transplants. No loss of damaged skin areas



**Day 14 p.o.**

Complete engrafting of STSG and healing of wounds. Good pliability and gliding of transplanted areas

\*\* Courtesy of Dr. Kamolz, Vienna, Austria

**Surgical Challenges:**

- Wound closure where primary surgical closure is unlikely
- Avoidance of scar tissue formation and adhesion to facilitate easy metal removal
- Reduction of restrictive scar formation
- Reduction of infection risk during osteosynthetic treatment
- Achieve a full-thickness outcome without donor site morbidity

**MatriDerm® Tissue Regeneration Concept**

- Quality in Efficacy: Cost effective one-step procedure
- Quality in Structure: Turns a split-thickness skin graft into full skin quality
- Quality of Life: Superior functional and aesthetic outcome

# Publications.

2010:

## Articles

### Burns and Reconstruction:

Bloemen MC, van Leeuwen MC, van Vucht NE, van Zuijlen PPM, Middelkoop E. Dermal substitution in acute burns and reconstructive surgery: A 12-year follow-up. *Plast Reconstr Surg* 2010;125(5):1450-9

Haslik W, Kamolz LP, Manna F, Hladik M, Rath T, Frey M. Management of full thickness skin defects in the hand and wrist region: first long-term experiences with the dermal matrix MatriDerm®. *J Plast Reconstr Aesthet Surg* 2010;63(2): 360-4

Atherton DD, Tang R, Jones I, Jawad M. Early excision and application of MatriDerm® with simultaneous autologous skin grafting in facial burns. *Plast Reconstr Surg* 2010;125(2):60e-61e

### Exposed Tendon:

Ryssel H, Andreas Radu C, Germann G, Otte M, Gazyakan E. Single-stage MatriDerm® and skin grafting as an alternative reconstruction in high-voltage injuries. *International Wound Journal*, Epub doi: 10.1111/j.1742-481X.2010.00703.x

Boyce A, Atherton DD, Tang R, Jawad M. The use of MatriDerm® in the management of an exposed Achilles tendo secondary to a burn injury. *J Plast Reconstr & Aesthet Surg* 2010; 63(2):e206-7; Epub 2009 Mar 26

### Necrotising Fasciitis:

Ryssel H, Germann G, Czermak C, Kloeters O, Gazyakan E, Riedel K. MatriDerm® in depth-adjusted reconstruction of necrotising fasciitis defects. *Burn* 201; 12 Apr: pp

### Diabetic Ulcer:

Cervelli V, Lucarini L, Cerretani C, Spallone D, Palla L, Brinci L, De Angelis B. The use of MatriDerm® and autologous skin grafting in the treatment of diabetic ulcers: a case report. *International Wound Journal* 2010; 7(4):291-296

### Review:

Van der Veen VC, Van der Waal MBA, Van Leeuwen MCE, Ulrich MMW, Middelkoop E. Biological background of dermal substitutes. *Burns* 2010; 36: 305-321

## Congress Abstracts

### Burns, Necrotising Fasciitis, Reconstruction:

Ryssel H, Germann G, Gazyakan E. 5-Years (357 cases) of experience with MatriDerm® in Burns, Necrotizing Fasciitis, High Voltage Injuries and Reconstructive Surgery. The John A. Boswick Burn and Wound Care Symposium 2010: Oral presentation

### Trauma:

Öhlbauer M., Hageleit B., Rapp Ph., Militz M. Einsatz von MatriDerm® bei Avulsionsverletzungen. DGPRÄC 2010: Poster presentation.

### Burns:

Ryssel H, Germann G, Reichenberger M, Kloeters O, Gazyakan E, Radu CA. Dermal substitution with MatriDerm® in burns of the dorsum of the hand. The John A. Boswick Burn and Wound Care Symposium 2010: Oral presentation.

Middelkoop E, Bloemen MCT, van Zuijlen PPM. Long term effectiveness of dermal substitutes in scar management. 3rd International SCAR Club Meeting 2010: Keynote Presentation

Dantzer E. IntegraTM DRT-BL (Bi-Layer) vs MatriDerm® in hand burns. 3rd MEGA HAND International Symposium 2010: Oral presentation

Duchamel P. IntegraTM DRT-BL vs. MatriDerm® in hand burns. 3rd MEGA HAND International Symposium 2010: Oral presentation

Rennekampff O. MatriDerm® in hand burns. 3rd MEGA HAND International Symposium 2010: Oral presentation

Brea-García B, Taboada-Suarez A, Couto-González I, Álvarez-González. Collagen-Elastin MatriDerm® histological integration on split-thickness skin grafts receptor sites on clinical practice: preliminary results. 3rd International SCAR Club Meeting 2010: Poster presentation

Kamolz LP, Roka J, Haslik W, Lumenta DB, Frey M. Einsatzmöglichkeiten der V.A.C Therapie in der chirurgischen Behandlung von Verbrennungen. *ZfW* 2010: No A: Suppl

2009

**Articles**

**Exposed:**

Wetzig T, Gebhardt C, Simon JC. New Indications for artificial Collagen-Elastin Matrices? Covering Exposed Tendons. *Dermatology* 2009; 219(3):272-3

**Chronic and Acute Wounds:**

Téot L, Otman S, Faure C. Dermal Regeneration Templates: Technical Characteristics and value in Acute and Chronic Wounds. *J Wound Tech* 2009; (4): 25 – 29

**Animal:**

Schneider J, Biedermann T, Widmer D, Montano I, Meuli M, Reichmann E, Schiestl C. MatriDerm® versus Integra: A comparative experimental study. *Burns* 2009; 35: 51-57

**Review:**

Lumenta DB, Kamolz LP, Frey M. adult Burn Patients With More Than 60% TBSA Involved-Meek and Other Techniques to Overcome Restricted Skin harvest Availability-The Viennese Concept. *J Burn Care & Research* 2009;30(2):231-42

Lou RB, Hickerson WL. The Use of Skin Substitutes in Hand Burns. *Hand Clin* 2009. 25: 497–509

Kamolz LP, Kitzinger HB, Karle B, Frey M. The treatment of hand burns. *Burns* 2009; 35: 327-337

**Basic Research:**

Keck M, Haluza D, Burjak S, Eisenbock B, Kamolz LP, Frey M. Cultivation of keratinocytes and preadipocytes on a collagen-elastin scaffold (MatriDerm®). First results of an in vitro study. *Eur Surg* 2009; 4174: 189-193

Golinski PA, Zöller N, Kippenberger S, Menke H, Bereiter-Hahn J, Bernd A. Entwicklung eines transplantierbaren Hautäquivalentes auf Basis von MatriDerm® mit menschlichen Keratinozyten und Fibroblasten. *Handchir Mikrochir Plast Chir* 2009;41(6):327-32

Ryssel H, Germann G, Reichenberger M. Therapie allschichtiger Hautdefekte mit MatriDerm® als dermales Substitut. *Plast Chir* 2009; 3:

**Congress Abstracts**

**Burns and Reconstructive:**

Kamolz LP, Haslik W, Hladik M, Frey M. Use of Collagen Elastin Matrix (MatriDerm®) for Dermal Reparation in a One-stage Procedure: Long Term Results in the Treatment of Severe Hand Burn Injuries. The John A. Boswick Burn and Wound Care Symposium 2009: Oral presentation

Dantzer E, Kenane N, Ascencio Y, Meaudre E, Goutorbe P. Dermal Equivalent and Epidermal Graft in a One Single Surgical Step Procedure for Acute Burn and Post Burn Reconstructive Surgery. 41st Annual Meeting American Burn Association: Oral presentation

Bloemen M, Van Leeuwen M, Van Vucht P, Van Zuijlen P, Middelkoop E. Dermal Substitution in Acute Burns and Reconstructive Surgery: a 12-Year Follow-up. European Burn Association 2009: Poster presentation

Zakine G, Yassine A, Forme N, bahe L, Atlan M. Place of the new dermal matrix in burn and reconstructive surgery. European Burn Association 2009: Poster presentation

Rennekampff OH, Xu M, Nolte S, Rodemann H. In Vitro Evaluation of a Fibroblast seeded Collagen/Elastin Matrix (MatriDerm®) –implication for In vivo Use. 41st Annual Meeting American Burn Association: Oral presentation

Penile reconstruction:

Duncan RT, Dunn GW. MatriDerm® and V.A.C. A Case of Complex Penile Reconstruction. European Burn Association 2009: Poster presentation

Chronic Wounds:

Scheffer P, Schepler H. Möglichkeiten von MatriDerm® als alloplastisches Biomaterial im Einsatz bei chronischen Wunden. 12. Jahreskongress der deutschen Gesellschaft für Wundheilung und Wundbehandlung e.V. 2009

**Basic Research:**

Keck M, Haluza D, Lumenta D, Burjak S, Kamolz LP, Frey M. MatriDerm® as a scaffold for a adipose tissue engineering. First results of an in vitro study with pretreated and non-treated human preadipocytes. 27. Jahrestagung der Deutschsprachigen Arbeitsgemeinschaft für Verbrennungsbehandlung: Oral presentation

**2008****Articles****Burns:**

Ryssel H, Gazyakan E, German G, Öhlbauer M. The use of MatriDerm® in early excision and simultaneous autologous skin grafting in burns –A pilot study. *Burns* 2008; 34: 93-97

Haslik W, Kamolz LP, Manna F, Hladik M, Rath T, Frey M. Management of full thickness skin defects in the hand and wrist region: first long-term experiences with the dermal matrix MatriDerm®. *J Plast Reconstr Aesthet Surg* 2008, Epub 1-5

Kolokythas P, Aust MC, Vogt PM, Paulsen F. Aktuelle Übersicht zum Dermisersatz mit Kollagen-Elastin-Matrix MatriDerm® bei Brandverletzungen. *Handchir Mikrochir Plast Chir* 2008; 40: 367-371

Keck M, Ueberreiter K. Erfolgreiche Korrektur einer adhärennten Narbe im Bereich des Handrückens mit MatriDerm®. *Handchir Mikrochir Plast Chir* 2008; 40: 197-200

**Review:**

Kamolz LP, Lumenta DB, Kitzinger HB, Frey M. Tissue Engineering for cutaneous wounds: an overview of current standards and possibilities. *Eur Surg* 2008; 40/1: 19-26

Behr B, Megerle KO, Germann G, Kloeters O. Neue Konzepte in der Oberflächentherapie bei Verbrennungswunden. *Handchir Mikrochir Plast Chir* 2008; 40: 361-366

Grill CJ, Haslik W, Rab M, Koller R. Thermische Läsion im Fußbereich. *J FuSpru* 2008; 6: 96-98

Pallua N, Demir E. Rekonstruktive Chirurgie nach Verbrennungstrauma. *Plast Chir* 2008; Suppl 2: 105-107

**2007****Articles****Burns:**

Haslik W, Kamolz LP, Nathschläger G, Andel H, Meissl G, Frey M. First experience with the collagen-elastin matrix MatriDerm® as a dermal substitute in severe burn injuries of the hand. *Burns* 2007; 33: 364-368

Kamolz LP, Haslik W, Frey M. Die Kollagen-Elastin-Matrix MatriDerm® als Dermisersatz bei schweren Handverbrennungen. *Plast Chir* 2007, 4:1-5

**Basic Research:**

Bruns S, Stark Y, Wieland M, Stahl F, Kasper, Scheper T. Fast and efficient screening system for new biomaterials in tissue engineering. A model for peripheral nerve regeneration. *J Biomed Mater Res* 2007, 81A: 736-747

## 2006

### **Articles**

#### **Burns:**

Kolokythas P, Vogt PM. Aktuelle Hautersatzmaterialien in der Verbrennungschirurgie. *Plast Chir* 2006; 3: 108-114

Kamolz LP, Kitzinger HB, Andel H, Frey M. The surgical treatment of acute burns. *Eur Surg* 2006; 38/6: 417-423

#### **Basic Research:**

Stark Y, Suck K, Kasper C, Wielnd M, van Griesen M, Scheper T. Application of collagen matrices for cartilage tissue engineering. *Experim Tox Pathol* 2006; 57: 305-311

## 2002

### **Articles**

#### **Burns and reconstruction:**

Van Zuijlen PPM, Lamme E, van Galen MJM, van Marle J, Kreis RW, Middelkoop E. Long term results of a clinical trial on dermal substitution. A light microscopy and Fourier analysis based evaluation. *Burns* 2002; 28: 151-160

## 2000

### **Articles**

#### **Burns and reconstruction:**

Van Zuijlen PPM, van Trier A, Vloemans JFPM, Groenvelt F, Kreis RW, Middelkoop E. Graft Survival and Effectiveness of Dermal substitution in Burns and reconstructive Surgery in a One-stage Grafting Model. *Plast Reconstr Surg* 2000; 106:615-623




**matriderm<sup>®</sup>**  
Based on **TRC** Technology

Tissue Regeneration Concept – In a One-Step Procedure.

# Secures the Quality of Your Work.

- Quality in Efficacy: Cost effective one-step procedure
- Quality in Structure: Turns a split-thickness skin graft into full skin quality
- Quality of Life: Superior functional and aesthetic outcome

	Ref-Nr.	Size
<b>DIN A4</b>	83500 - 100	210 x 297 x 1mm
	83400 - 100	210 x 297 x 2mm
<b>DIN A6</b>	83403 - 100	105 x 148 x 1mm
	83401 - 100	105 x 148 x 2mm
<b>DIN A8</b>	83404 - 100	52 x 74 x 1mm



Vertrieb/Distribution Schweiz/FL:



Industriestrasse 26  
CH-5036 Oberentfelden  
Tel: 0848 848 948 | Fax: 0848 848 949  
info@medicalsol.ch | www.medicalsol.ch

