

Initial Experience Using a Hyaluronate-Iodine Complex for Wound Healing

ROBERT A. BRENES, M.D., MICHAEL S. AJEMIAN, M.D., SHADY H. MACARON, M.D.,
LUCIAN PANAIT, M.D., STANLEY J. DUDRICK, M.D.

From Saint Mary's Hospital, The Stanley J. Dudrick Department of Surgery, Waterbury, Connecticut

Hyaluronate-iodine complex is a wound healing adjuvant approved for use in the European Union. The objective of this study is to validate hyaluronate-iodine as a potential wound healing agent. Patients were recruited from the hospital, the outpatient clinic, and the wound healing center. Hyaluronate-iodine soaked gauze was applied to wounds either daily or every other day depending on the amount of wound exudate. Wounds were measured weekly, and progression was documented with digital photography. All wounds were debrided as needed using standard surgical techniques. Fourteen patients (19 wounds) were entered into this prospective study, and 10 patients completed treatment. Fourteen wounds progressed to complete healing with a mean healing time of 18.1 ± 15.1 weeks. Treatment was interrupted in four patients. One patient discontinued treatment due to pain related to application of hyaluronate-iodine, another patient for transportation issues, and the other two patients were lost to follow-up due to relocation out of state and noncompliance with scheduled appointments. Hyaluronate-iodine was helpful in the healing of all types of wounds treated in this pilot study. The antiadhesive and antimicrobial properties of hyaluronate-iodine create a desirable environment conducive to wound healing without apparent detrimental effects.

FOR MORE THAN 150 years, iodine has been used as an antiseptic for the treatment of wounds. Its bactericidal efficacy was first described by Davaine in 1880, but it was not until the 19th century that surgeons found use for it as a preoperative disinfectant.¹ One of its drawbacks was that it caused acute pain and irritation on application; however, to overcome these limitations, iodophors (or iodine carriers) were developed.² These iodophors act as a reservoir of the active "free" iodine.³

The mechanism of action of iodine is unknown; however, it is believed that it simultaneously adversely affects multiple sites in microbial cells, and rapidly penetrates the cell wall, thereby disrupting protein synthesis.^{1, 4} Early criticism of iodine claimed deleterious effects on wound healing because of its strong cytotoxic properties. Indeed, one study described impaired wound healing and reduced wound strength.⁵ Newer literature suggests that the older studies of iodine are not entirely reliable due to discrepancies with study conditions with regard to animal *versus* human research, *in vivo versus in vitro* conditions, and differences in preparations and concentrations of iodine.^{1, 6}

More recent articles indicate a beneficial effect on wound healing by new formulations of iodine-containing compounds as compared with older iodinated agents.^{1, 7}

Moore et al.⁸ demonstrated that iodine induced TNF- α , causing an influx of macrophages and T-helper cells, which plays a positive role in promoting wound healing. Gilchrist⁶ also reported that iodine has a role in enhancing healing in chronic wounds.

Hyaluronan (HA), a glycosaminoglycan, is a naturally occurring component of the extracellular matrix in the skin.^{9, 10} It is arranged as a linear polysaccharide with repeating units of glucuronic acid and N-acetyl glucosamine. Since its discovery in 1934 by Meyer and Palmer, its properties have been thoroughly studied with relation to its effects on wound healing.¹¹

HA is capable of absorbing 1000 to 3000 times its own weight in water.^{12, 13} This absorptive property has a role in tissue hydration, entrapping water and ions, which provide cells a favorable environment in which to migrate.¹⁴ HA also enhances the motility of cells by binding to CD44 receptors and the receptor for HA-mediated motility on lymphocytes, inflammatory cells, and connective tissue cells.^{13, 14} Furthermore, HA has been demonstrated to bind to fibrin in clots causing them to swell and become more porous. This action facilitates migration, allowing monocytes, macrophages, and neutrophils from the periphery of the wound to migrate toward the center and promote the wound healing process.¹³

Address correspondence and reprint requests to Robert A. Brenes, M.D., Saint Mary's Hospital, The Stanley J. Dudrick Department of Surgery, 56 Franklin Street, Waterbury, CT 06706. E-mail: robert.brenes@stmh.org.

HA is also known to promote phagocytosis and angiogenesis.^{10, 13, 14} Rooney et al.¹⁵ showed that HA could stimulate fibroblast proliferation and synthesis of collagen. HA matrices enhance collagen deposition in a more orderly fashion with less degradation. More specifically, HA activates the proliferation and migration of keratinocytes and promotes dermal collagen remodeling during morphogenesis.^{16, 17}

In the Czech Republic, both agents were combined to make the wound healing complex hyaluronate-iodine also known as Hyiodine[®] (Contipro Group, Dolní Dobrouč, Czech Republic). Basic science studies have shown that hyaluronate-iodine speeds up the wound healing process by increasing the production of IL-6 and TNF- α by lymphocytes.¹⁸ These proinflammatory mediators stimulate keratinocyte and fibroblast proliferation and migration.¹⁹ Subsequently, Sobotka et al. have shown hyaluronate-iodine complex to be effective clinically in healing diabetic wounds.^{20, 21}

The objective of this study was to determine if the hyaluronate-iodine complex can be used as a potential wound healing agent in a variety of indolent wounds.

Methods

Institutional review board approval was obtained, and patients were prospectively enrolled into the study, which was undertaken in a 250-bed community teaching hospital. Participation was entirely voluntary, and informed consent was obtained for topical application of the experimental wound dressing. Patients with indolent wounds were recruited from the hospital, the outpatient clinic, and the wound healing center.

Hyaluronate-iodine soaked gauze was applied to wounds either daily or every other day, depending on the amount of wound exudate. Strict dressing change protocols were followed by both the principal investigators and the Visiting Nurse Association (VNA) services. Dressings were changed by VNA services for outpatients throughout the week at home and by the principal investigators in the wound healing center during regular weekly follow-up visits. Inpatient dressings were changed only by the principal investigators. Each week, wound areas were measured, and healing progression was further documented using digital photography. All wounds were evaluated and debrided as needed using standard surgical techniques.

Results

Fourteen patients with 19 wounds were entered into the study over 2 years. Ten patients with 14 wounds underwent the entire treatment protocol and achieved complete wound healing. The mean healing time was 18.1 ± 15.1 weeks. Treatment was interrupted in four patients with five wounds (Table 1).

Three patients had four lower extremity stasis ulcers, which were treated with excellent healing results. A combination of compression therapy, lower extremity elevation, and hyaluronate-iodine dressings was used in all three patients. Intravenous antibiotics were used when appropriate in accordance with wound culture results. Complete healing of all four ulcers occurred in an average treatment period of 34 ± 19.6 weeks.

One patient had multiple bilateral lower extremity venous stasis ulcers, providing a unique opportunity

TABLE 1. Individual Patient Characteristics

	Type of Wound	Measurement – Start	Measurement – End	% of Wound Remaining	Length of Treatment
Patient 1	Chronic venous insufficiency ulcer	190.4 cm ²	0 cm ²	0%	62 weeks
	Acute venous insufficiency ulcer	50 cm ²	0 cm ²	0%	33 weeks
Patient 2	Lower extremity stasis ulcer	4 cm ³	0 cm ³	0%	21 weeks
Patient 3	Chronic venous insufficiency ulcer	1.76 cm ²	0 cm ²	0%	20 weeks
	Acute traumatic lower extremity wound	3.6 cm ²	0 cm ²	0%	18 weeks
Patient 4	Chronic left groin wound	28 cm ²	0 cm ²	0%	18 weeks
Patient 5	Surgical abdominal wound	24 cm ³	0 cm ³	0%	3.5 weeks
Patient 6	Surgical abdominal wound	8 cm ³	0 cm ³	0%	19 weeks
	Surgical abdominal wound	64 cm ³	0 cm ³	0%	19 weeks
Patient 7	Surgical abdominal wound	48.95 cm ²	9.89 cm ²	20%	22 weeks
Patient 8	Diabetic foot ulcer	5.5 cm ²	2.4 cm ²	43%	12 weeks
	Diabetic foot ulcer	11.16 cm ²	0.34 cm ²	3%	12 weeks
Patient 9	Diabetic foot ulcer, osteomyelitis, and MRSA	6 cm ²	0 cm ²	0%	16 weeks
Patient 10	Diabetic foot ulcer	14 cm ²	1.92 cm ²	13%	20 weeks
Patient 11	Diabetic leg ulcer	21.08 cm ²	0 cm ²	0%	5 weeks
Patient 12	Chronic traumatic pretibial wound	9.9 cm ²	0.21 cm ²	2%	49 weeks
Patient 13	Burn to thigh	13.16 cm ²	0 cm ²	0%	7 weeks
	Burn to thigh	14.7 cm ²	0 cm ²	0%	7 weeks
Patient 14	Perianal fistula with abscess s/p excision	3 cm ²	0 cm ²	0%	4.5 weeks

MRSA, methicillin-resistant *Staphylococcus aureus*; s/p, status post.

for a controlled trial. Left leg wounds were treated with hyaluronate-iodine whereas the right leg wounds (control) were treated with papain-urea and compression therapy as previously used before enrollment of the patient into the study. Both legs were debrided using standard surgical techniques as necessary. Each leg had a chronic wound as well as an acute wound. Control wounds *versus* wounds treated with hyaluronate-iodine were plotted using the Gompertz model for area-time relation (Figs. 1 & 2). The chronic control wound had a reduction of 38 per cent in area over 62 weeks, whereas the chronic wound treated with hyaluronate-iodine completely healed in the same amount of time. The acute control wound had a 45 per cent reduction in area in 33 weeks whereas the wound treated with hyaluronate completely healed during the same time period.

Four patients with five postoperative wound infections underwent treatment after groin dissection (Fig. 3), open cholecystectomy, open sigmoid resection for perforated diverticulitis, and small bowel resection for obstruction. Treatment was discontinued in one of these patients secondary to inability to

tolerate burning sensations associated with hyaluronate-iodine application; this patient was the only participant who experienced adverse symptoms related to the treatment. The other three patients having four wounds all progressed to complete healing within an average treatment time of 14.9 ± 7.6 weeks with no untoward effects of hyaluronate-iodine application.

Four diabetic patients having five lower extremity ulcers were enrolled into the study. One patient, with two wounds, was lost to follow-up due to relocation out of the state after 12 weeks of therapy. One foot ulcer was near complete healing, and the other was only one-half the original size at discontinuation of treatment. The second patient was lost to follow-up due to non-compliance with treatment appointments. After 20 weeks of hyaluronate-iodine treatment, he had only 13 per cent of the original wound area remaining to heal. The third diabetic patient had osteomyelitis with exposed bone and positive methicillin-resistant *Staphylococcus aureus* cultures. She received appropriate

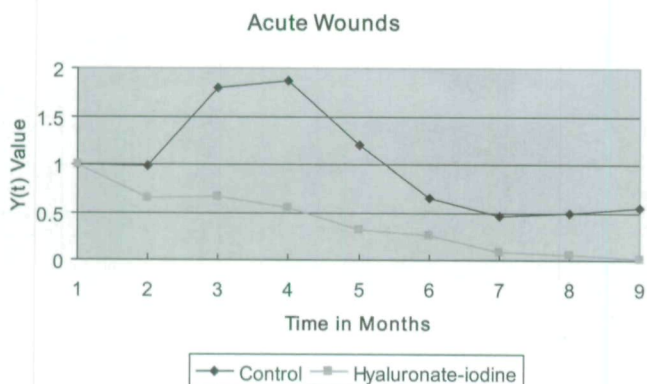


FIG. 1. Gompertz model for area-time relation of acute ulcers for patient 1.

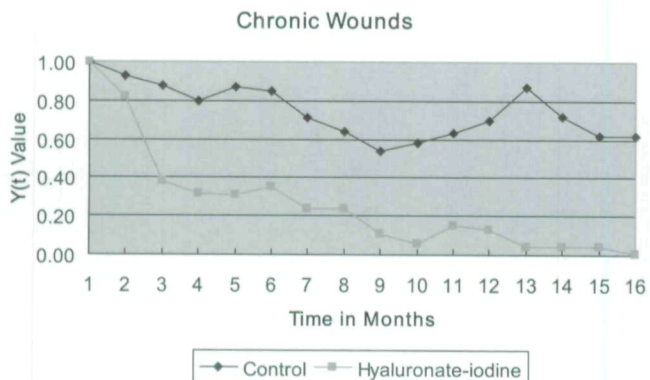


FIG. 2. Gompertz model for area-time relation of chronic ulcers for patient 1.

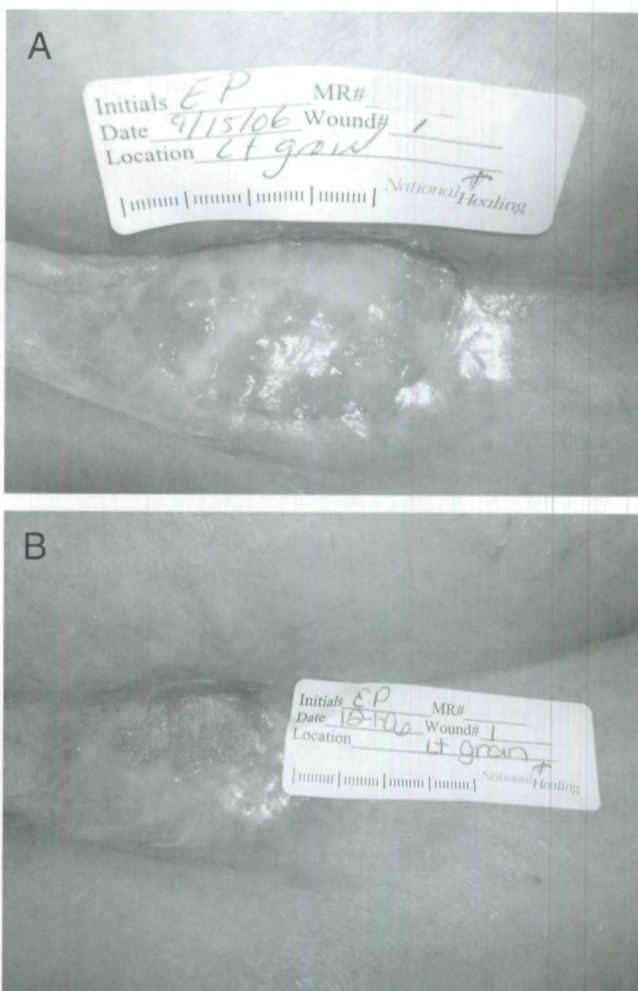


FIG. 3. (A) Chronic groin wound before treatment with hyaluronate-iodine. (B) Chronic groin wound with granulation tissue after 12 weeks of treatment with hyaluronate-iodine.

long-term intravenous antibiotics, and progressed to complete wound healing in 16 weeks. The fourth patient in this subgroup healed completely in only 5 weeks of hyaluronate-iodine dressings.

Two patients having three traumatic wounds all experienced complete wound healing with hyaluronate-iodine therapy in an average time of 10.7 ± 6.4 weeks. One patient had traumatic lower extremity wounds, whereas the other patient experienced third degree burns to both thighs. Another patient with a traumatic lower extremity wound discontinued treatment after 49 weeks of therapy due to insufficient funds for transportation to and from the wound healing center. The wound at that time was 98 per cent healed (Fig. 4). The burn wounds responded well to hyaluronate-iodine after less than optimal results with split thickness skin graft therapy. Both wounds completely healed after 7 weeks of therapy.

The last patient in this pilot study underwent surgical excision of a perianal fistula with abscess. The post-operative, contaminated, open perianal wound progressed to completely heal after only 4.5 weeks of therapy with hyaluronate-iodine.

Discussion

There have been a few studies in the Czech Republic demonstrating hyaluronate-iodine as an effective wound healing agent.^{20, 21} This is the first United States study to validate these reports. In this study, hyaluronate-iodine is a safe and efficacious wound healing agent for a variety of wounds including traumatic, diabetic, postoperative, and stasis ulcers. All wounds were treated using standard techniques, including weekly debridement, compression therapy, elevation, and antibiotics as indicated.

Complete healing was observed in patients who were compliant with the therapy regimen. Of the wounds that healed completely, the majority (12 out of 15) healed in 21 weeks or less, with five healing in less than 7 weeks. The two wounds, which required 49 and 62 weeks to heal, were both lower extremity wounds complicated by severe edema, which was difficult to control despite elevation and compressive therapy. As expected, the rate of healing varied among the different types of wounds in the patients studied, depending upon the complexity of the wounds, the presence and severity of infection, and the variability of the immunogenic response. Nonetheless, healing rates were generally better than those obtained previously using standard techniques without hyaluronate-iodine, and were consistent with published reports from the Czech Republic.

Several wounds were complicated by infection, which when treated appropriately with antibiotics, and

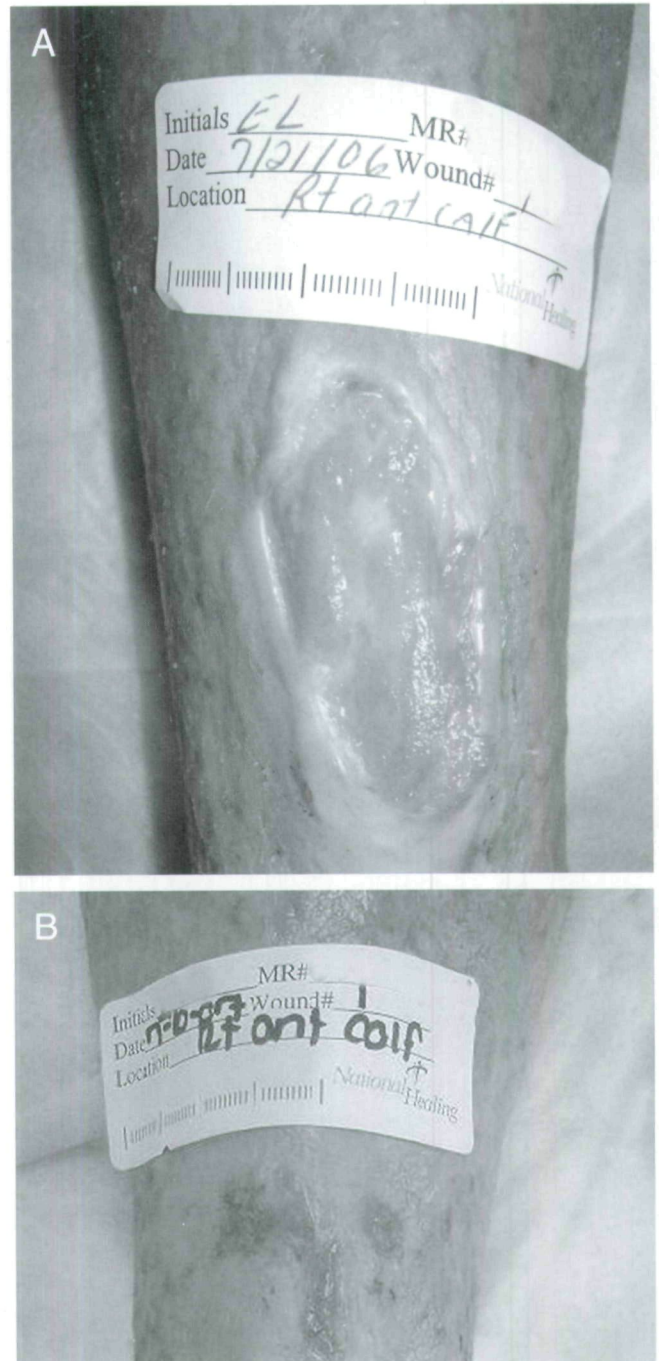


FIG. 4. (A) Chronic traumatic pretibial wound before treatment with hyaluronate-iodine; (B) Chronic traumatic pretibial wound after 48 weeks of treatment with hyaluronate-iodine.

concurrently with hyaluronate-iodine, did not prevent healing. One patient with exposed bone and methicillin-resistant *Staphylococcus aureus* osteomyelitis healed during 16 weeks of intravenous antibiotics as an adjunct to the protocol. Hyaluronate-iodine therapy was also beneficial in the healing of lower extremity stasis ulcers of both venous and lymphatic origin. Most of the patients in this preliminary study group had failed treatment or had delayed healing with other wound

TABLE 2. *Treatments Before Hyaluronate-Iodine Complex*

Previous Wound Healing Treatments	
Patient 1	Collagenase, papain-urea
Patient 4	Hydrofiber dressing, V.A.C.
Patient 5	Wet-to-dry dressings
Patient 7	Hydrofiber dressing, V.A.C., castor oil-balsam of Peru-trypsin ointment
Patient 9	Wet-to-dry dressings
Patient 10	Castor oil-balsam of Peru-trypsin ointment, hydrocellular dressing
Patient 11	Castor oil-balsam of Peru-trypsin ointment, hydrocellular dressing
Patient 12	Collagen and oxidized regenerated cellulose, hydrocellular dressing, hydrofiber dressing, V.A.C.
Patient 14	Wet-to-dry dressings

V.A.C., vacuum assisted closure.

healing modalities, but responded to treatment with hyaluronate-iodine (Table 2).

The purpose of this uncontrolled pilot study was to gain experience with this agent, which is being used in the Czech Republic where it has been developed as a wound healing adjuvant. Our intention was simply to add use of topical hyaluronate-iodine to our established wound treatment regimens to determine if it might improve healing and decrease healing time as has been reported in the European literature. As a result of our preliminary studies, we have initiated a prospective, randomized, controlled study in our institution to acquire the data necessary to determine the role and effectiveness of this agent, which is new to the United States. Our further intention is to stimulate others interested in wound care and healing to carry out similar studies to accumulate data in the large numbers and the variety of patients required to determine the role and value of hyaluronate-iodine in the management of indolent wounds. Lastly, we are hoping to encourage basic investigations of this agent in controlled, standardized animal wound healing models in the laboratories of university medical centers, which are not available in our community teaching hospital and wound healing center.

REFERENCES

1. Selvaggi G, Monstrey S, Van Landuyt K, et al. The role of iodine in antisepsis and wound management: a reappraisal. *Acta Chir Belg* 2003;103:241-7.
2. Cooper RA. Iodine revisited. *Int Wound J* 2007;4:124-37.

3. Gottardi W. Iodine and iodine compounds. In: Febiger L, ed. *Disinfection, Sterilization, and Preservation*. Philadelphia: Lea & Febiger, 1991, pp 152-66.
4. Gordon J. Clinical significance of methicillin-sensitive and methicillin-resistant *Staphylococcus aureus* in UK hospitals and the relevance of povidone-iodine in their control. *Postgrad Med J* 1993;69(Suppl 3):S106-16.
5. Kramer SA. Effect of povidone-iodine on wound healing: a review. *J Vasc Nurs* 1999;17:17-23.
6. Gilchrist B. Should iodine be reconsidered in wound management? European Tissue Repair Society. *J Wound Care* 1997;6:148-50.
7. Mayer D, Tsapogas M. Povidone-iodine and wound healing: a critical review. *Wounds* 1993;5:14-23.
8. Moore K, Thomas A, Harding KG. Iodine released from the wound dressing Iodosorb modulates the secretion of cytokines by human macrophages responding to bacterial lipopolysaccharide. *Int J Biochem Cell Biol* 1997;29:163-71.
9. Brown JA. The role of hyaluronic acid in wound healing's proliferative phase. *J Wound Care* 2004;13:48-51.
10. Voinchet V, Vasseur P, Kern J. Efficacy and safety of hyaluronic acid in the management of acute wounds. *Am J Clin Dermatol* 2006;7:353-7.
11. Meyer K, Palmer J. The polysaccharide of the vitreous humor. *J Biol Chem* 1934;107:629-34.
12. Jiang D, Liang J, Noble PW. Hyaluronan in tissue injury and repair. *Annu Rev Cell Dev Biol* 2007;23:435-61.
13. Anderson I. The properties of hyaluronan and its role in wound healing. *Prof Nurse* 2001;17:232-5.
14. Almond A. Hyaluronan. *Cell Mol Life Sci* 2007;64:1591-6.
15. Rooney P, Wang M, Kumar P, et al. Angiogenic oligosaccharides of hyaluronan enhance the production of collagens by endothelial cells. *J Cell Sci* 1993;105:213-8.
16. Price RD, Berry MG, Navsaria HA. Hyaluronic acid: the scientific and clinical evidence. *J Plast Reconstr Aesthet Surg* 2007;60:1110-9.
17. Price RD, Myers S, Leigh IM, et al. The role of hyaluronic acid in wound healing: assessment of clinical evidence. *Am J Clin Dermatol* 2005;6:393-402.
18. Frankova J, Kubala L, Velebny V, et al. The effect of hyaluronan combined with KI3 complex (Hyiodine wound dressing) on keratinocytes and immune cells. *J Mater Sci Mater Med* 2006;17:891-8.
19. Gallucci RM, Sloan DK, Heck JM, et al. Interleukin 6 indirectly induces keratinocyte migration. *J Invest Dermatol* 2004;122:764-72.
20. Sobotka L, Velebny V, Smahelova A, et al. Sodium hyaluronate and an iodine complex-Hyiodine-new method of diabetic defects treatment. *Vnitr Lek* 2006;52:417-22. (In Czech).
21. Sobotka L, Smahelova A, Pastorova J, et al. A case report of the treatment of diabetic foot ulcers using a sodium hyaluronate and iodine complex. *Int J Low Extrem Wounds* 2007;6:143-7.

Copyright of American Surgeon is the property of Southeastern Surgical Congress and its content may not be copied or emailed to multiple sites or posted to a listserv without the copyright holder's express written permission. However, users may print, download, or email articles for individual use.